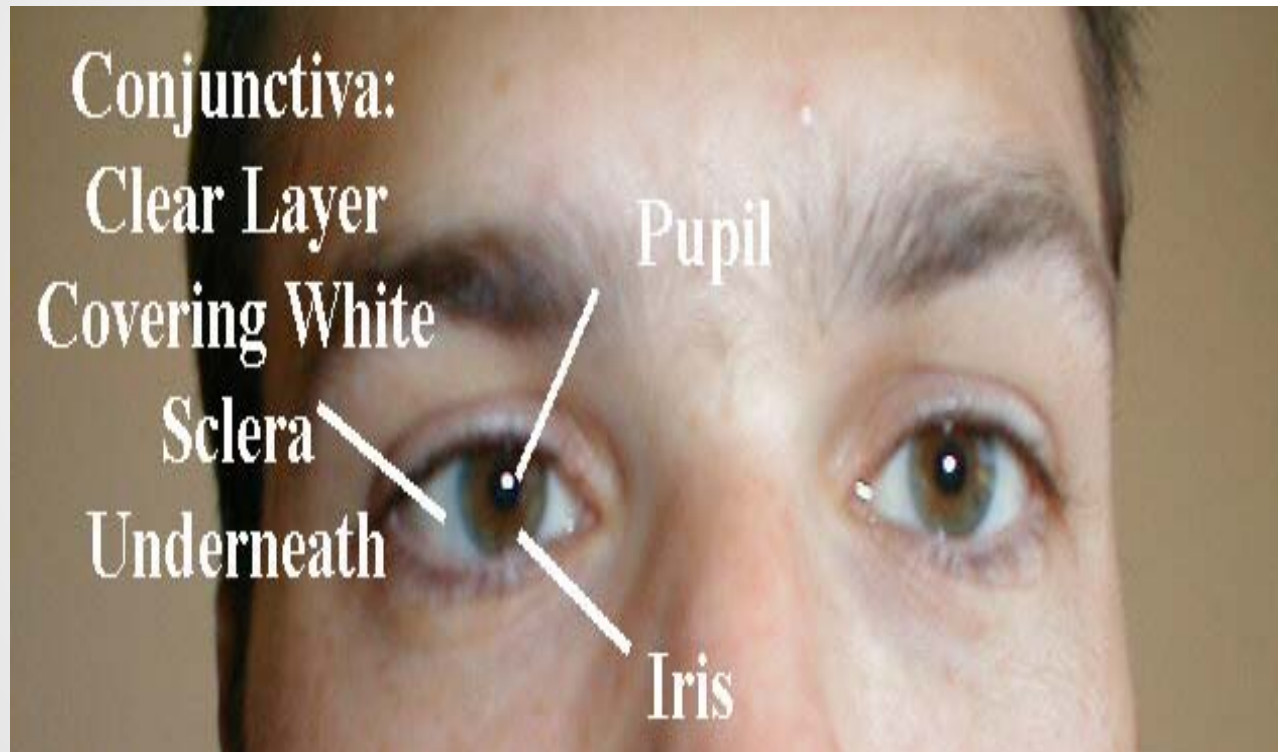


Primary Care Ophthalmology For Primary Care Physicians

Dr Layth Delaimy

General Consideration

- ▶ History
- ▶ General Examination
- ▶ Hand washing



The 8 Points

2 minutes examination

1. Visual Acuity
2. Visual Field
3. Extraocular Muscle motility
4. Pupils
5. External eye examination
6. Ocular Surface
7. Ophthalmoscope
8. Intra ocular pressure (not included)

1. Visual Acuity

- ◆ Near visual acuity (read small prints)

- ◆ Snellen Chart

E
F P
T O Z
L P E D
P E C F D
E D F C Z P

FELOPZD

DEFPOTEC

LEFODPCT

FDPLTCEO

FEZOLCFTD

1 20/200

2 20/100

3 20/70

4 20/50

5 20/40

6 20/30

7 20/25

8 20/20

9

10

11

70 ft - 21 m

60 ft - 18 m

50 ft - 15 m

40 ft - 12 m

30 ft - 9 m

20 ft - 6 m

15 ft - 4.5 m

10 ft - 3 m

7 ft - 2.1 m

4 ft - 1.2 m

G
WV
G S B E
N O I H W
J H E R L C
N O S Z L E P H

U L Y T H B X P G O

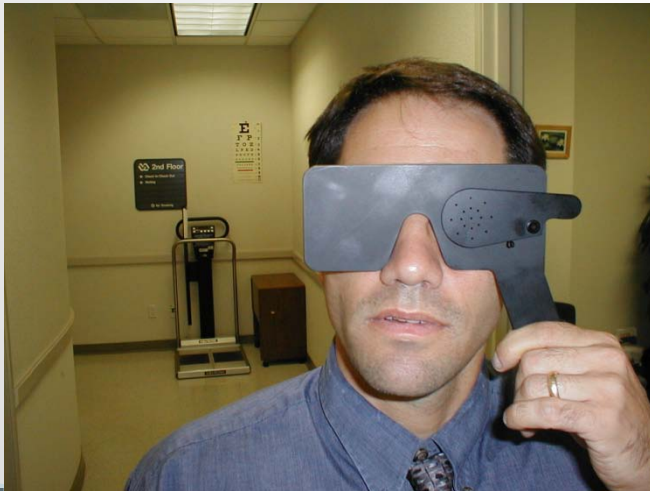S W M B W G C P T T

O H D C W N Y Z W A V

H N U O C I C R T W W D Q M V B F

Remember

- ▶ **Pinhole Testing:** The pinhole testing device can determine if a problem with acuity is the result of refractive error (and thus correctable with glasses) or due to another process. The pinholes only allow the passage of light which is perpendicular to the lens, and thus does not need to be bent prior to being focused onto the retina. The patient is instructed to view the Snellen chart with the pinholes up (below left) and then again with them in the down position (below right). If the deficit corrects with the pinholes in place, the acuity issue is related to a refractive problem.



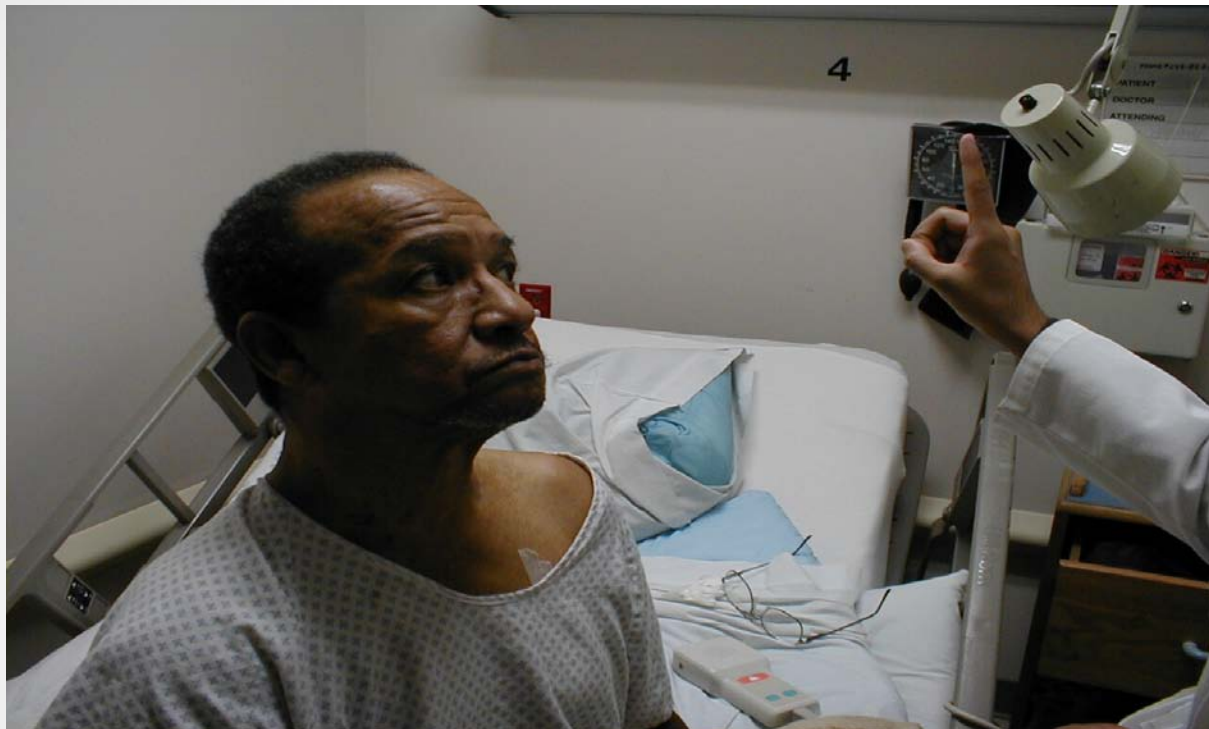2. Visual Fields

- ▶ Scotoma
- ▶ Finger counting
 - Check each eye then both
 - Counting or wiggling fingers
 - Test for scotoma

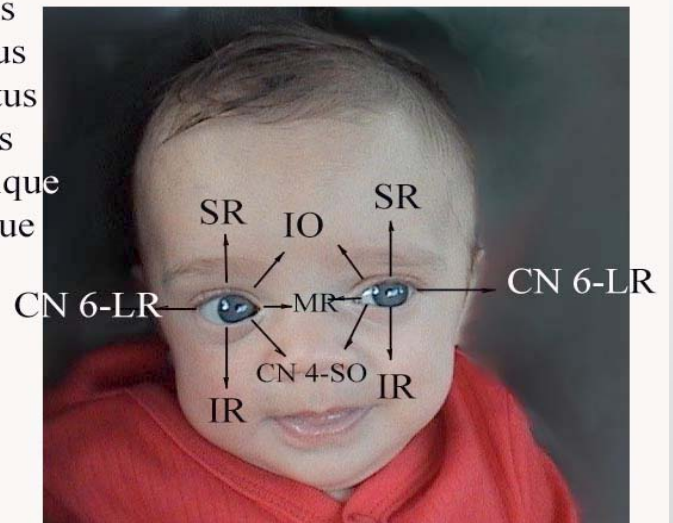
Extraocular muscle Motility

▶ Light Reflex

- If the dot of light (held in the middle) is in the middle of the pupil then the patient's eyes are likely to be aligned
- Follow the light of finger (with eyes only)
- Check the 6 cardinal directions



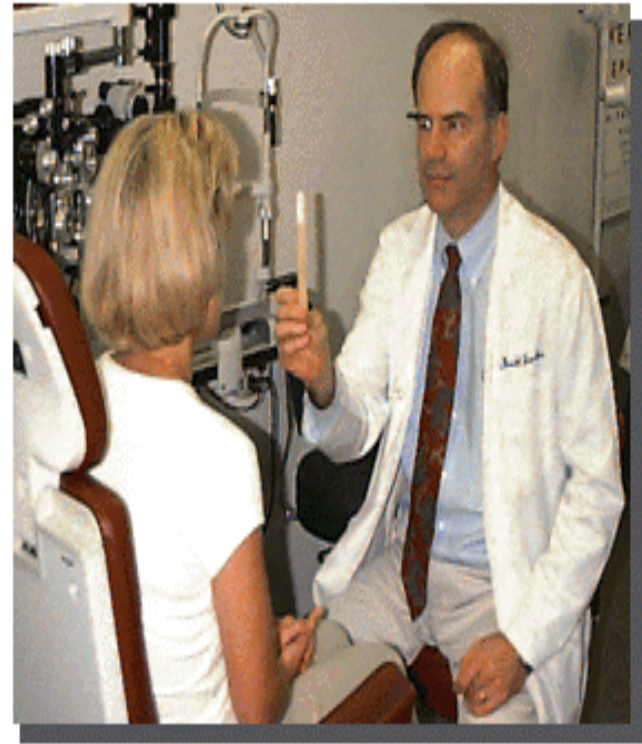
LR - Lateral Rectus
 MR - Medial Rectus
 SR - Superior Rectus
 IR - Inferior Rectus
 SO - Superior Oblique
 IO - Inferior Oblique



Cover Test

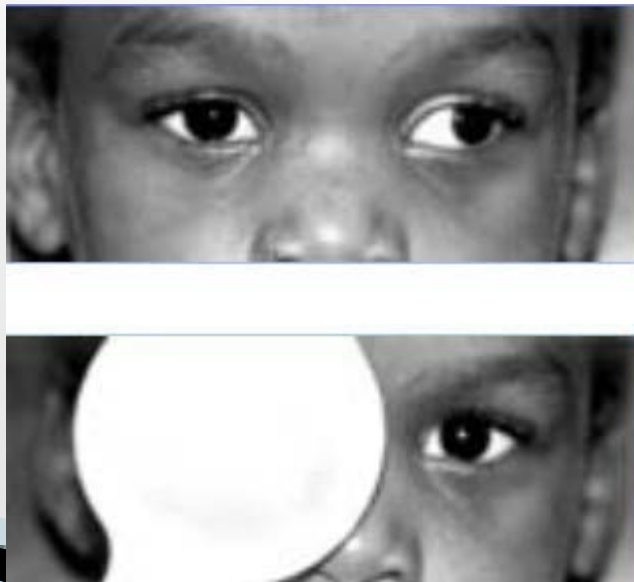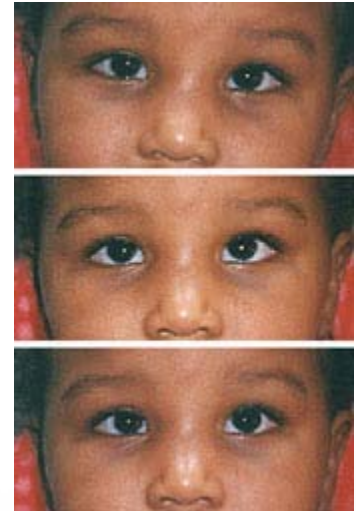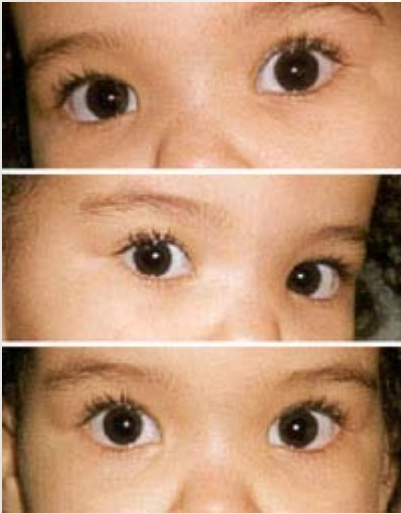Ask child to focus on an object, cover one eye, the abnormal eye with a squint will move to fixate

Explanation: Normally the normal eye fixates and the squinted does not. Thus, during test, when you cover the normal eye then the squinted one will fixate. When you remove the cover from the normal eye the abnormal eye will be squinted again.



- ▶ The first part of this test is the unilateral cover test. While wearing your corrective eyewear, you will be asked to **focus on a letter of the distance eye chart**. The Examiner will then cover your right eye while watching for a movement of the left eye. Upon removing the occluder, the examiner will wait for a few seconds to allow your eyes to return to equilibrium then will proceed by covering the left eye. If the eye not being covered moves to fixate the target (with both eyes open one eye is not aimed at the point of interest) that eye was not being used. This is referred to as a strabismus.
- ▶ The alternating cover test is very similar to the unilateral cover test but the main difference is that the occluder is switched from one eye to the next. If the eye just uncovered moves this is called a phoria. This means that in the resting position both eyes are not aimed at the target. Consequently, you must use effort to keep both eyes fixated on the target. This can cause eye strain and headaches. Prisms in your spectacles or visual training may be required.
- ▶ **Near Point of Convergence**
- ▶ The purpose of this test is to inspect your ability to converge your eyes. The practitioner will ask you to focus on a near target. As it is brought closer and closer to your nose, you will be asked when you first see two targets. There is a normal range at which you should be able to see a single target.

Quiz



4. Pupils

- ▶ Size, shape, figure & reactivity
- ▶ PEARL pupils are equal & reactive to light
- ▶ Direct & consensual responses
- ▶ Accommodation
 - From a far point to a near point the pupils constrict

5. Ocular Surface

- ▶ Conjunctiva: for redness & discharge
- ▶ Cornea: use **Fluorescence drop** if necessary
look for clarity & quality of light reflection
- ▶ Sclera
- ▶ Anterior chamber

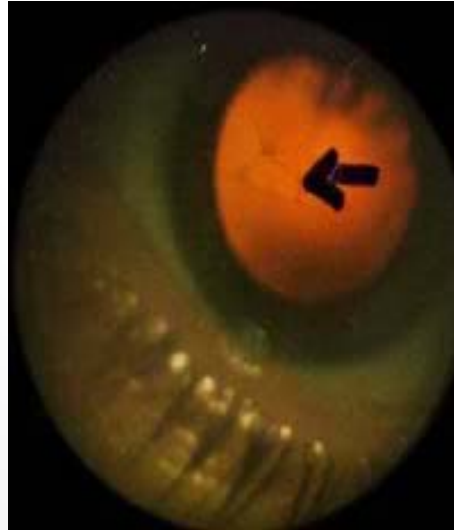
7. Ophthalmoscopy

- ▶ Remember LEFT LEFT LEFT & RIGHT RIGHT RIGHT
- ▶ Red reflex
- ▶ To dilate & not to dilate dilemma (not included in the 2 minutes exam)
 - Can precipitate acute angle glaucoma & may miss peripheral retinal lesions.
- ▶ Find a blood vessel follow it to the optic nerve
- ▶ Optic nerve:
 - Sharpness of the disc
 - Dilation of blood vessels
 - Presence of optic cup

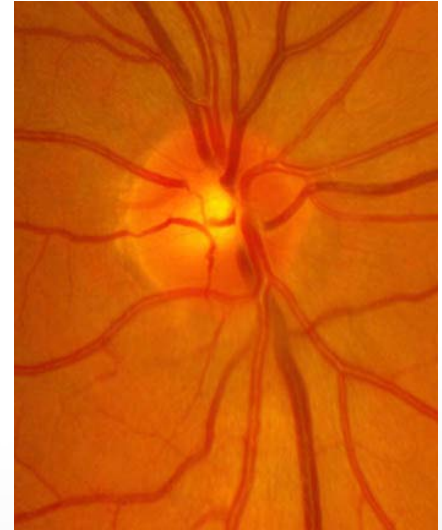
Ophthalmoscopy sequence



1



2

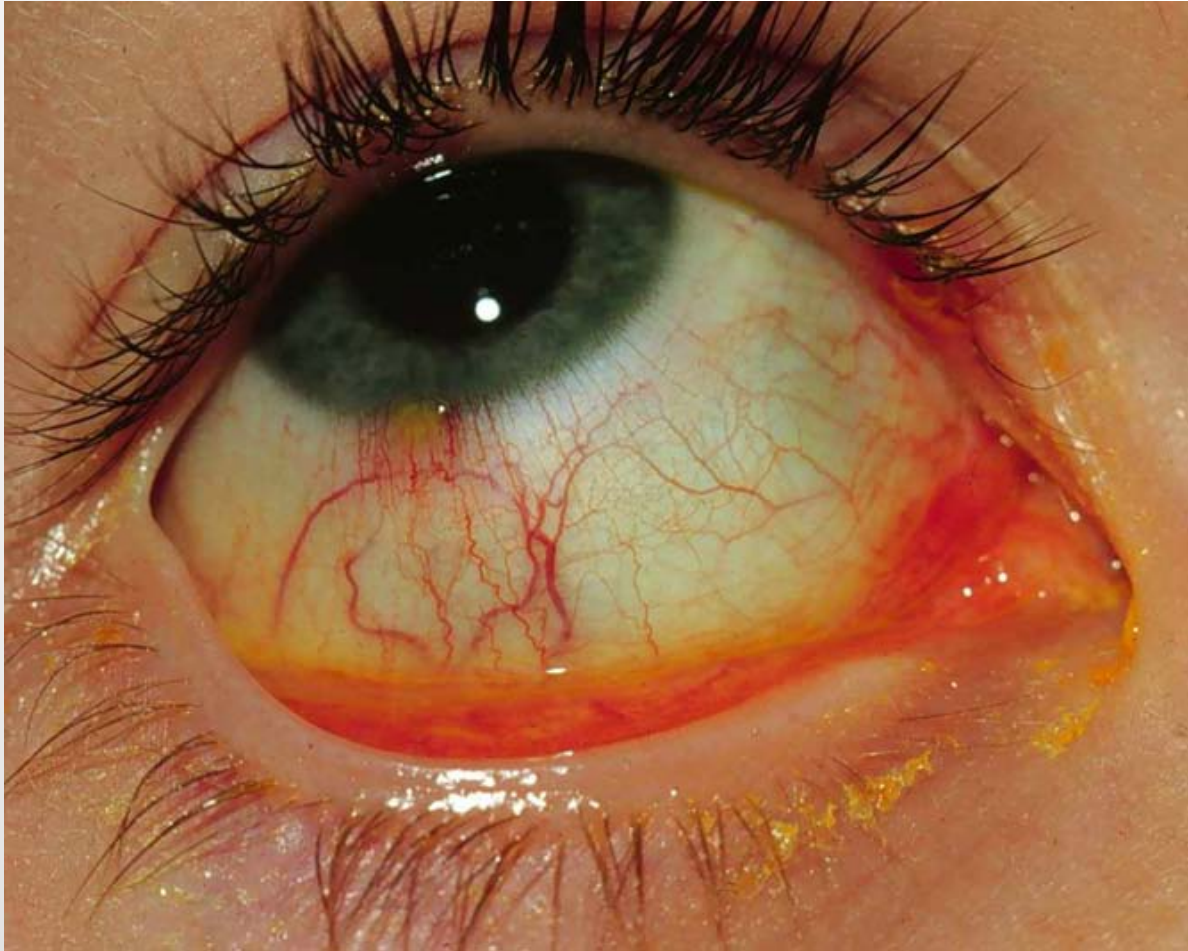

3

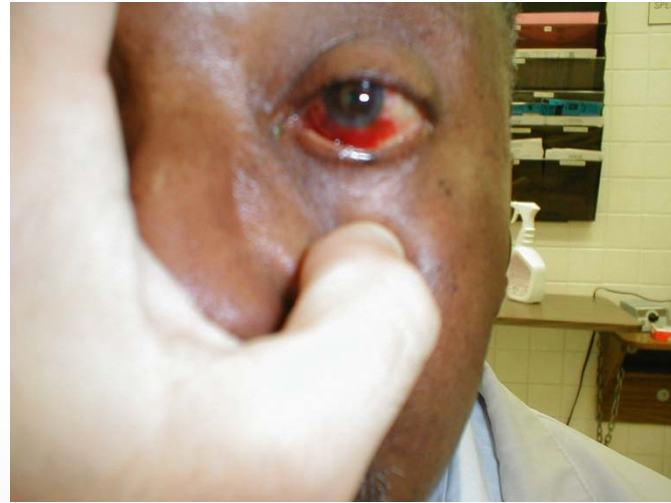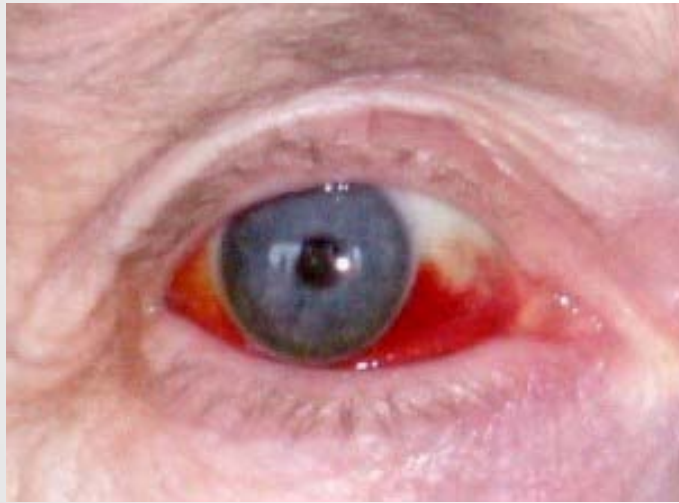
Intraocular pressure

- ▶ Tonometer
- ▶ Not included in 2 minutes exam

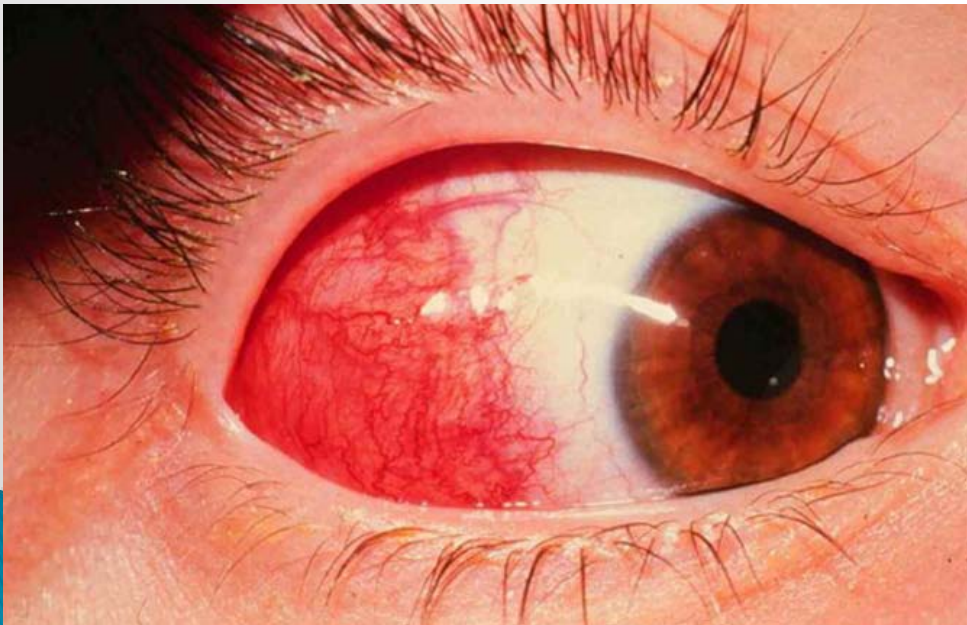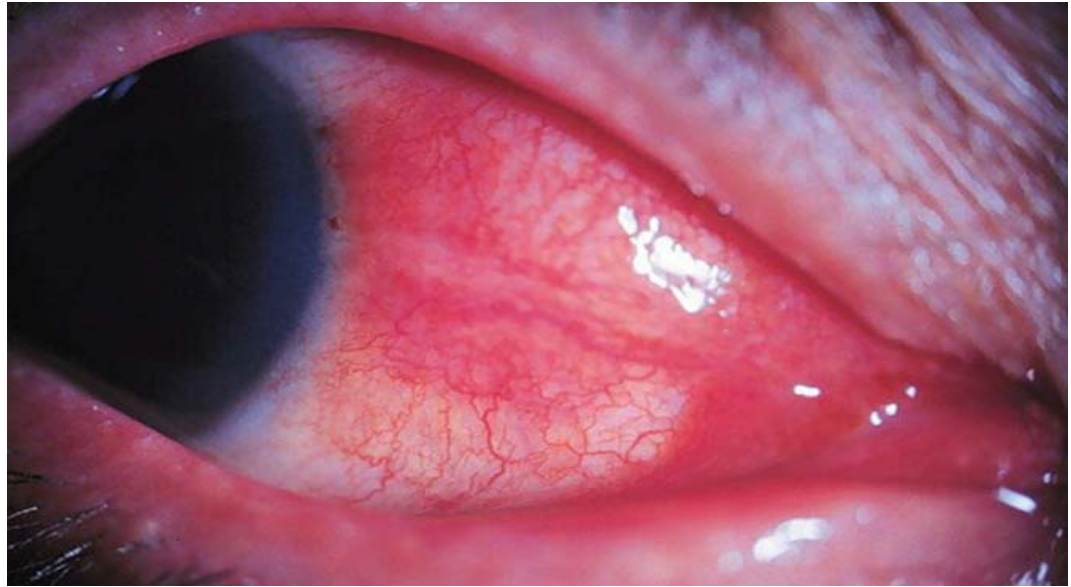Conjunctivitis



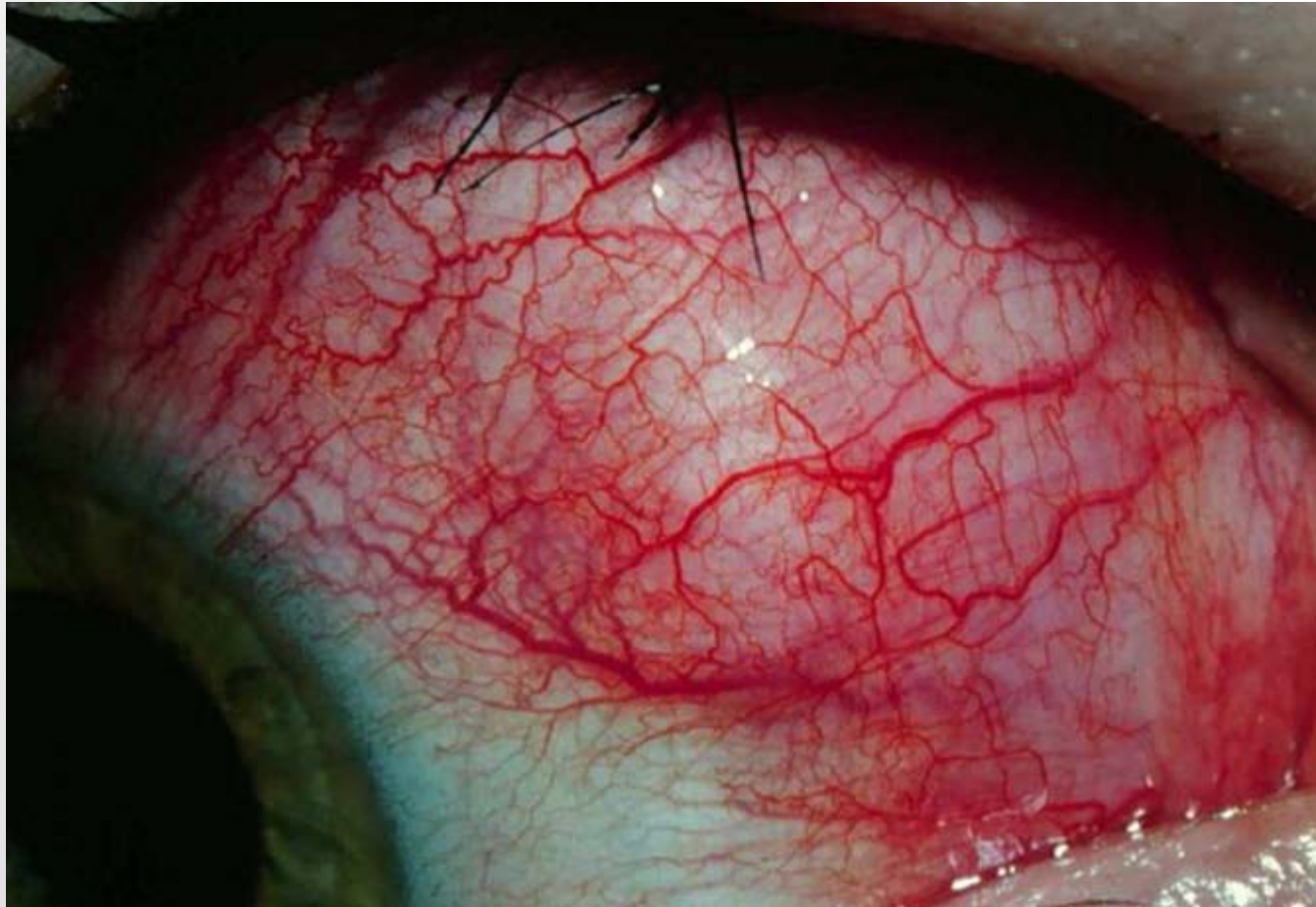
Subconjunctival Haemorrhage

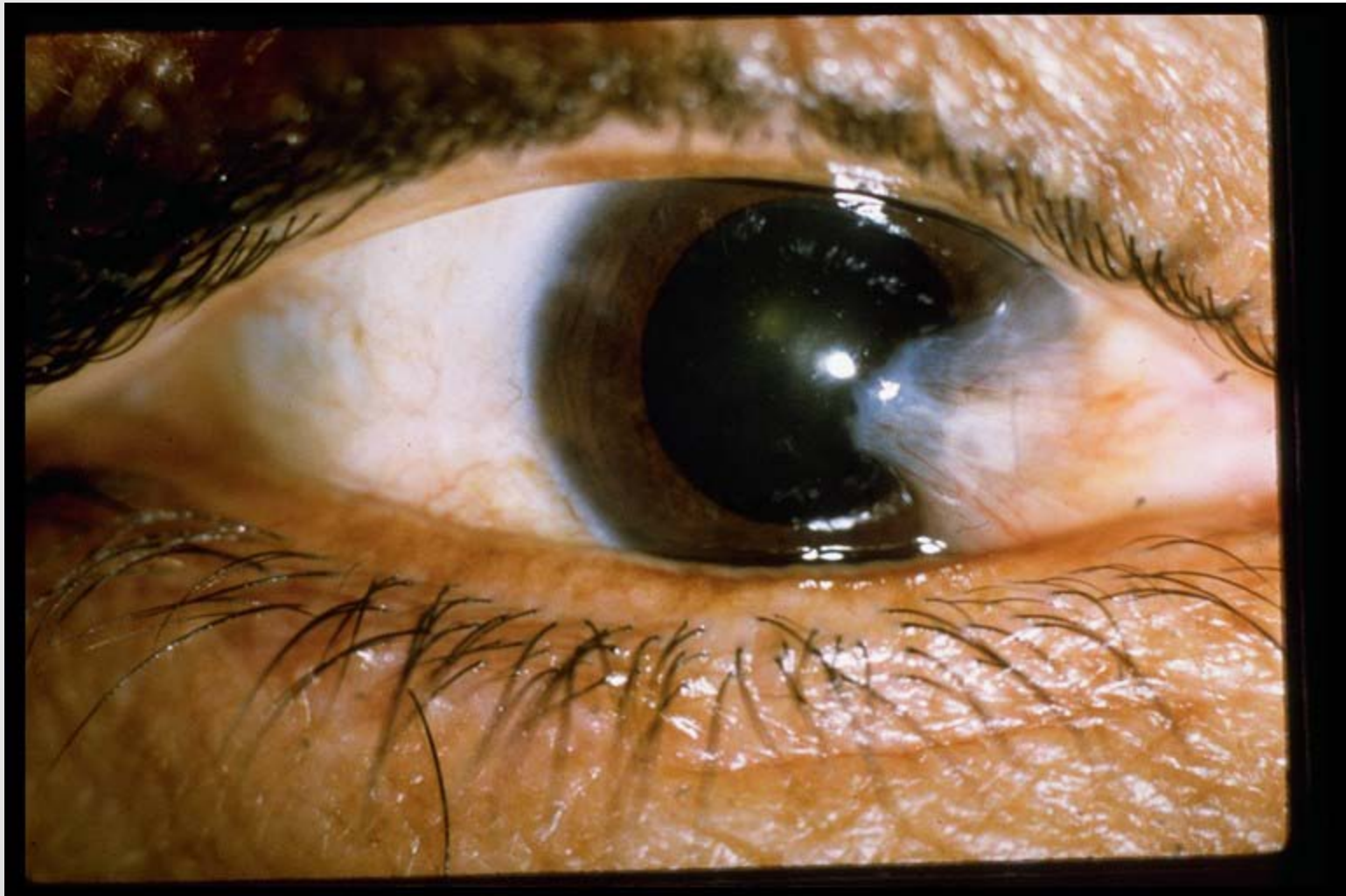

Episcleritis

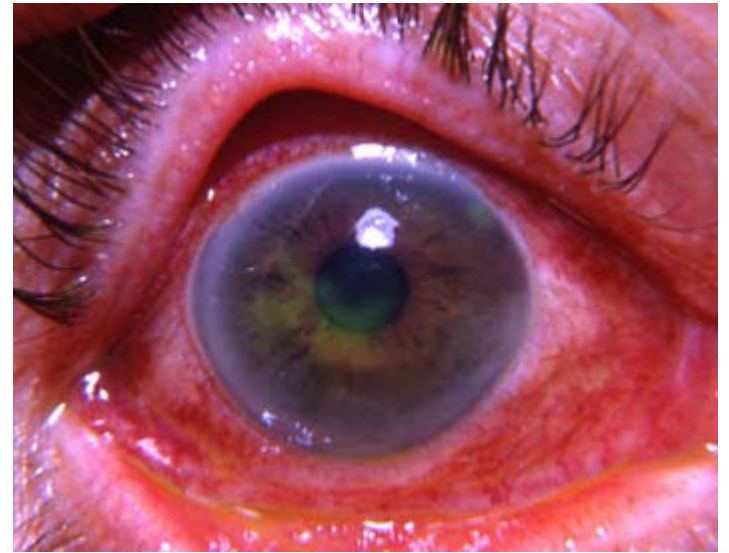
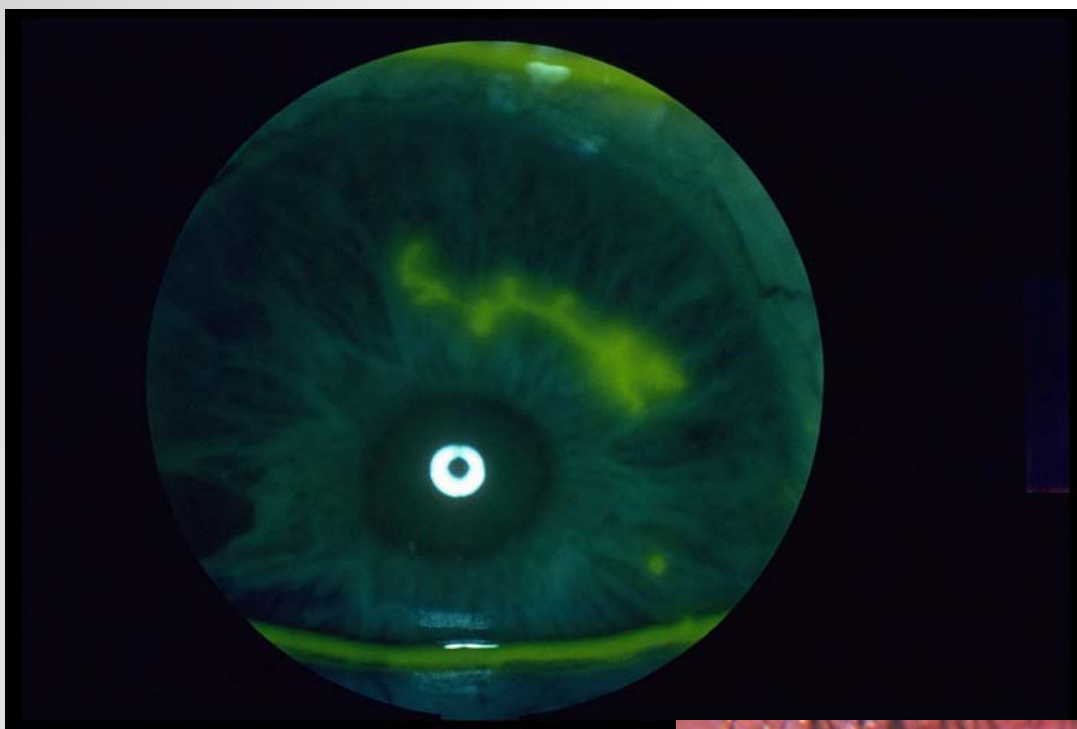


Scleritis

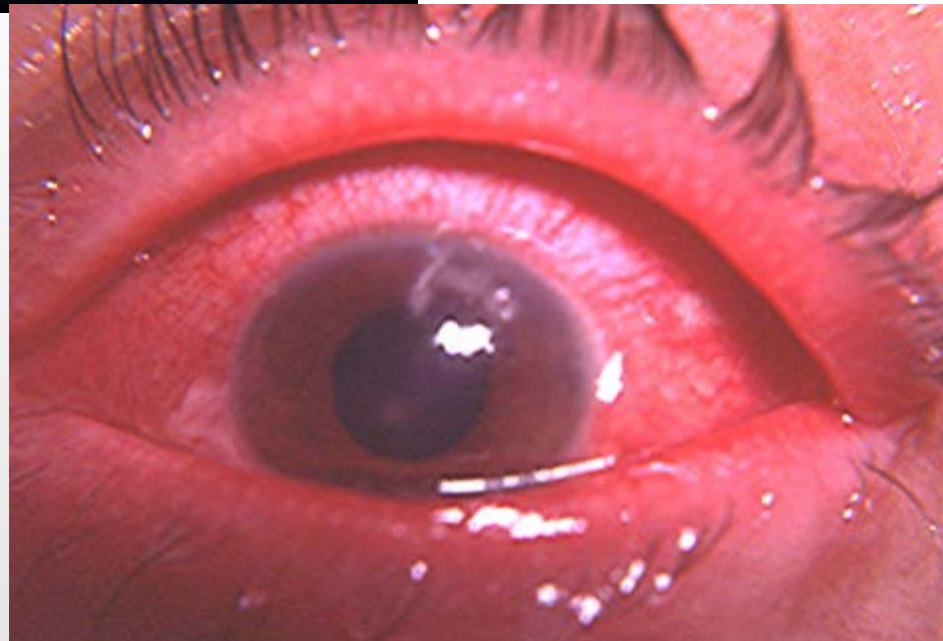

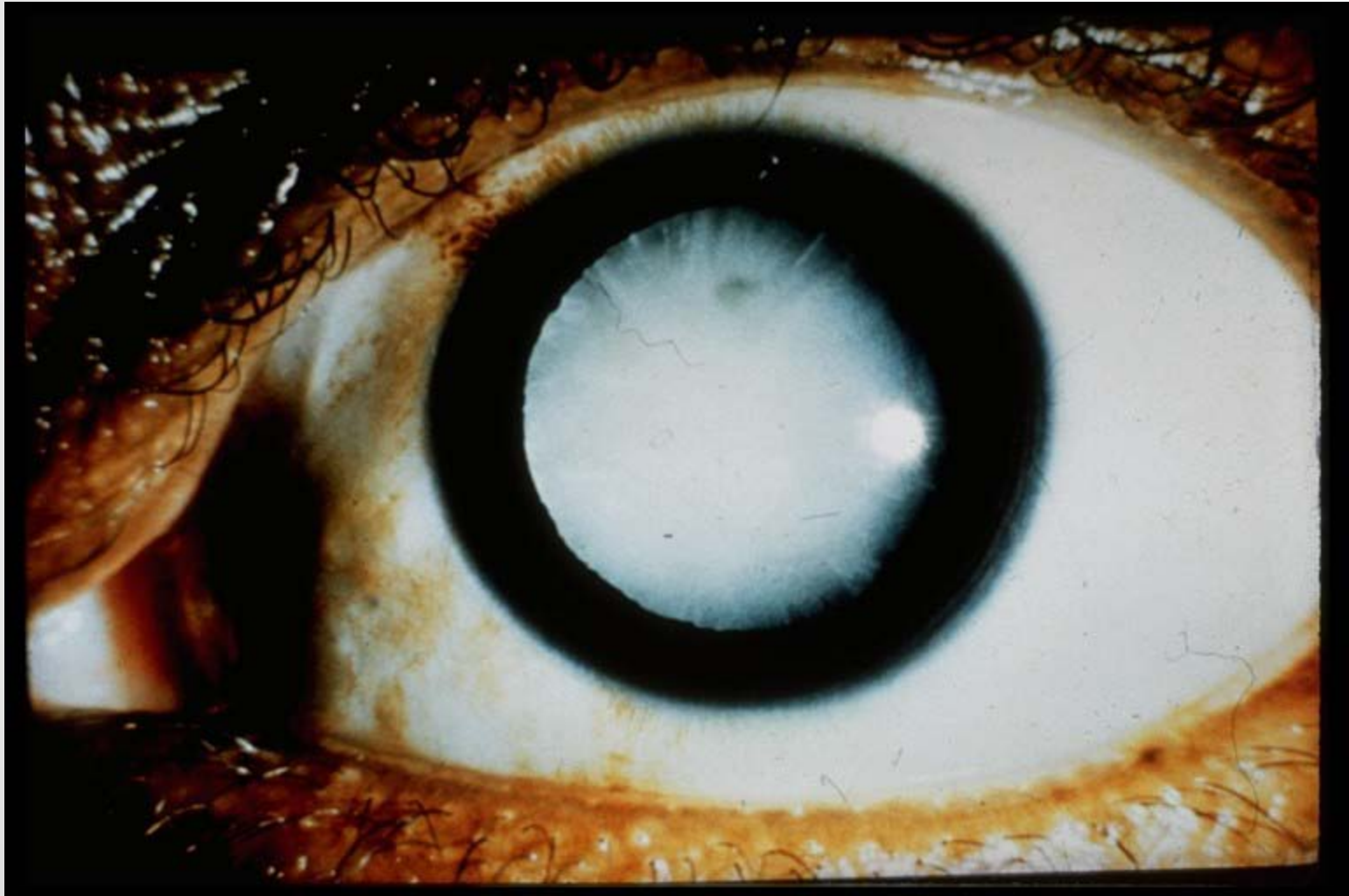


▶ pterygium



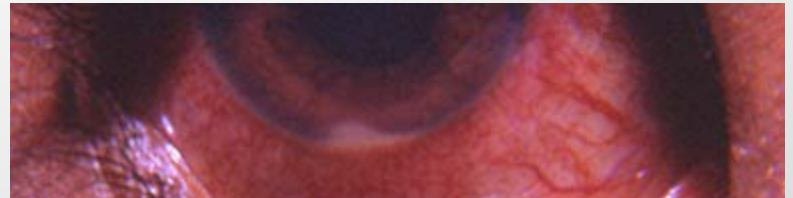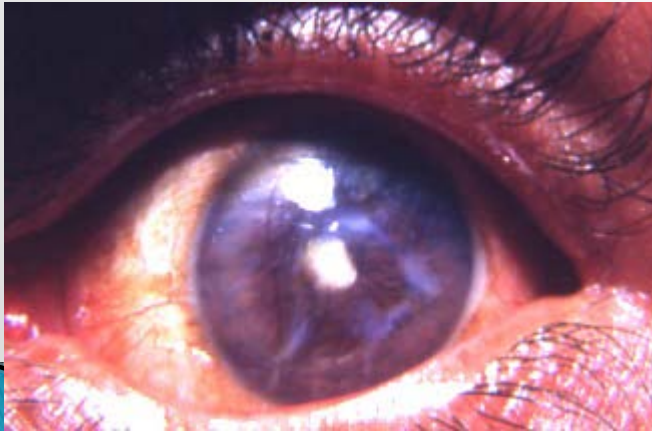
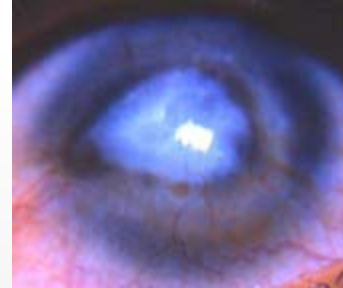
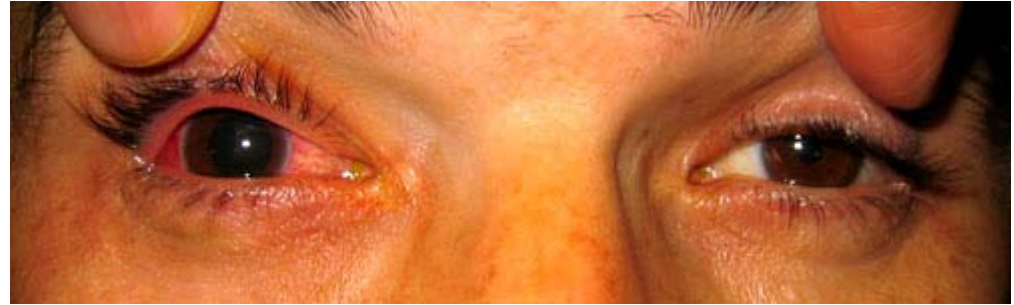
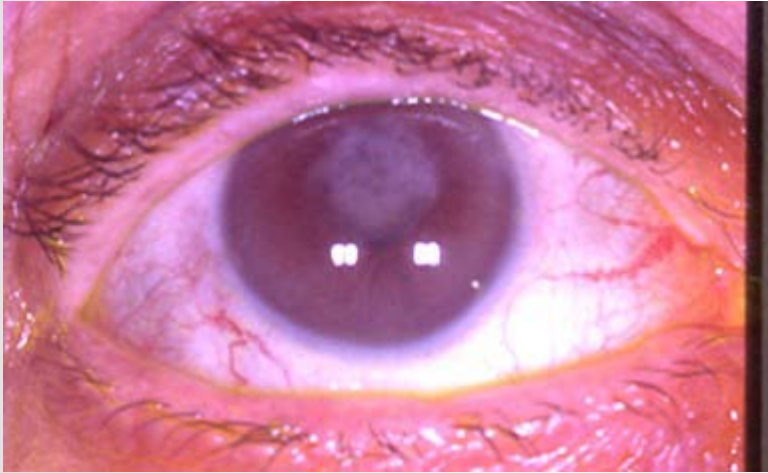► HZ Keratitis



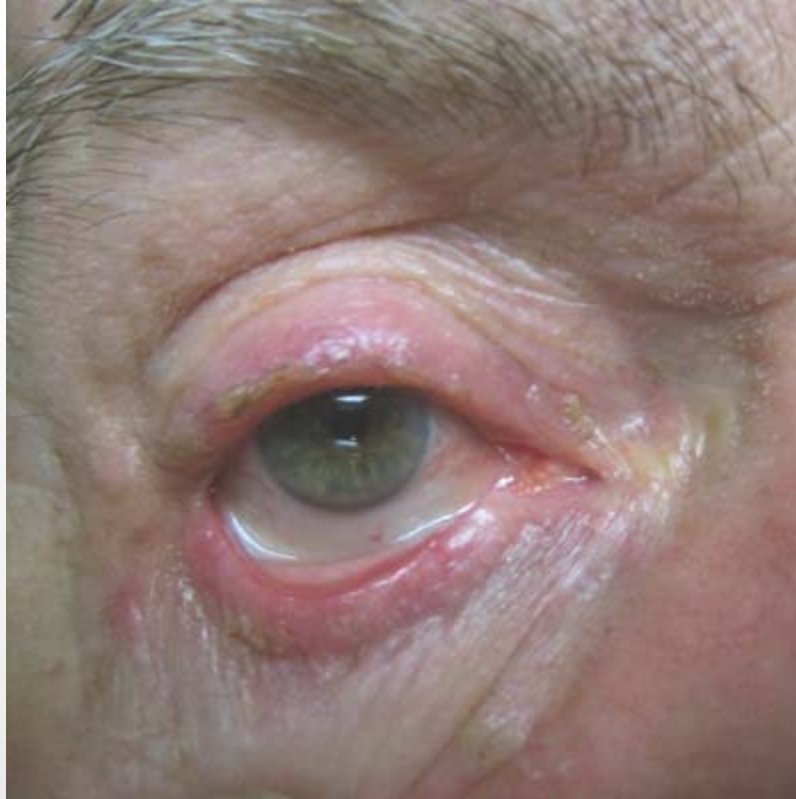


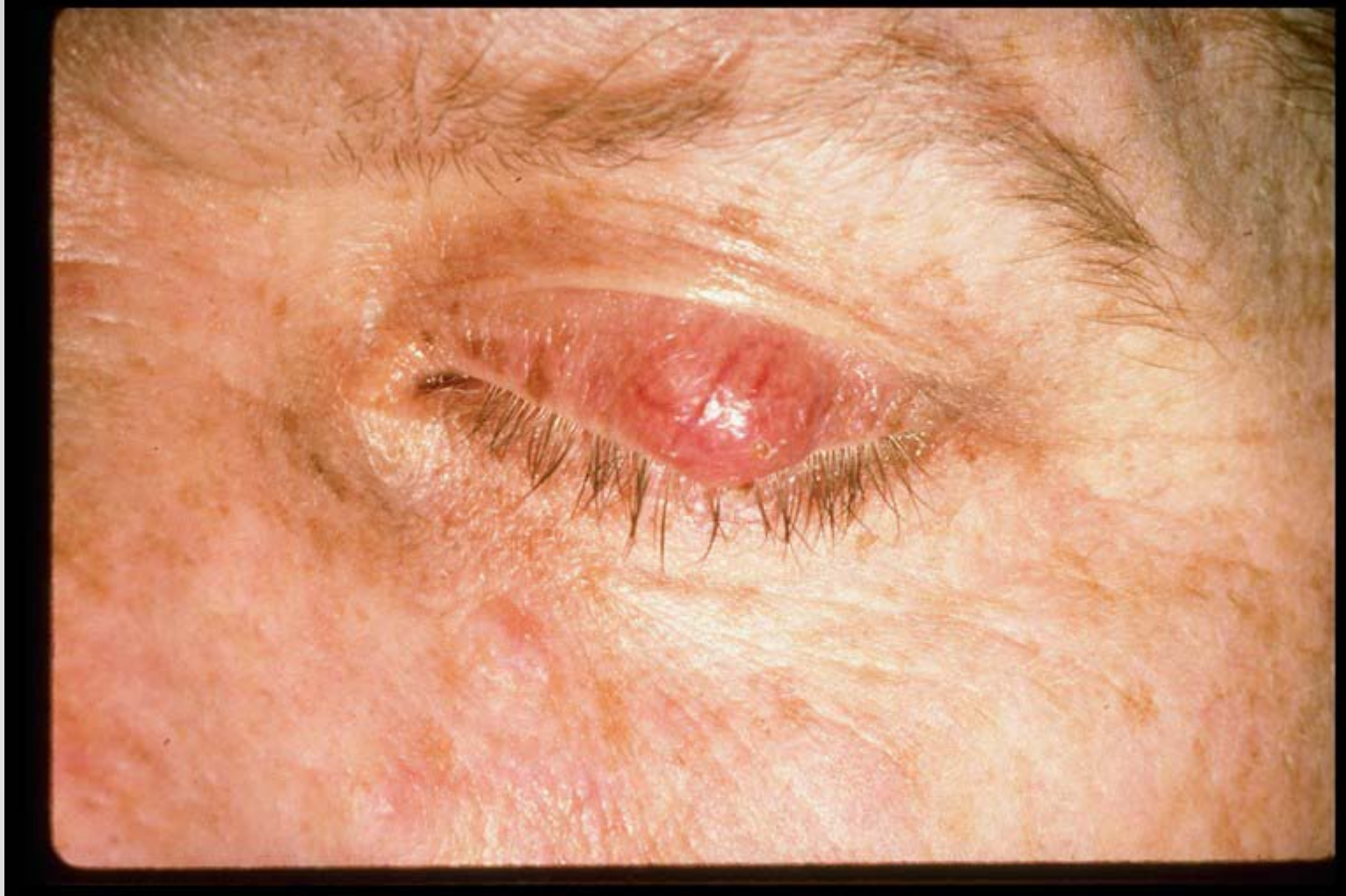Cataract

Iritis or ant. Uveitis

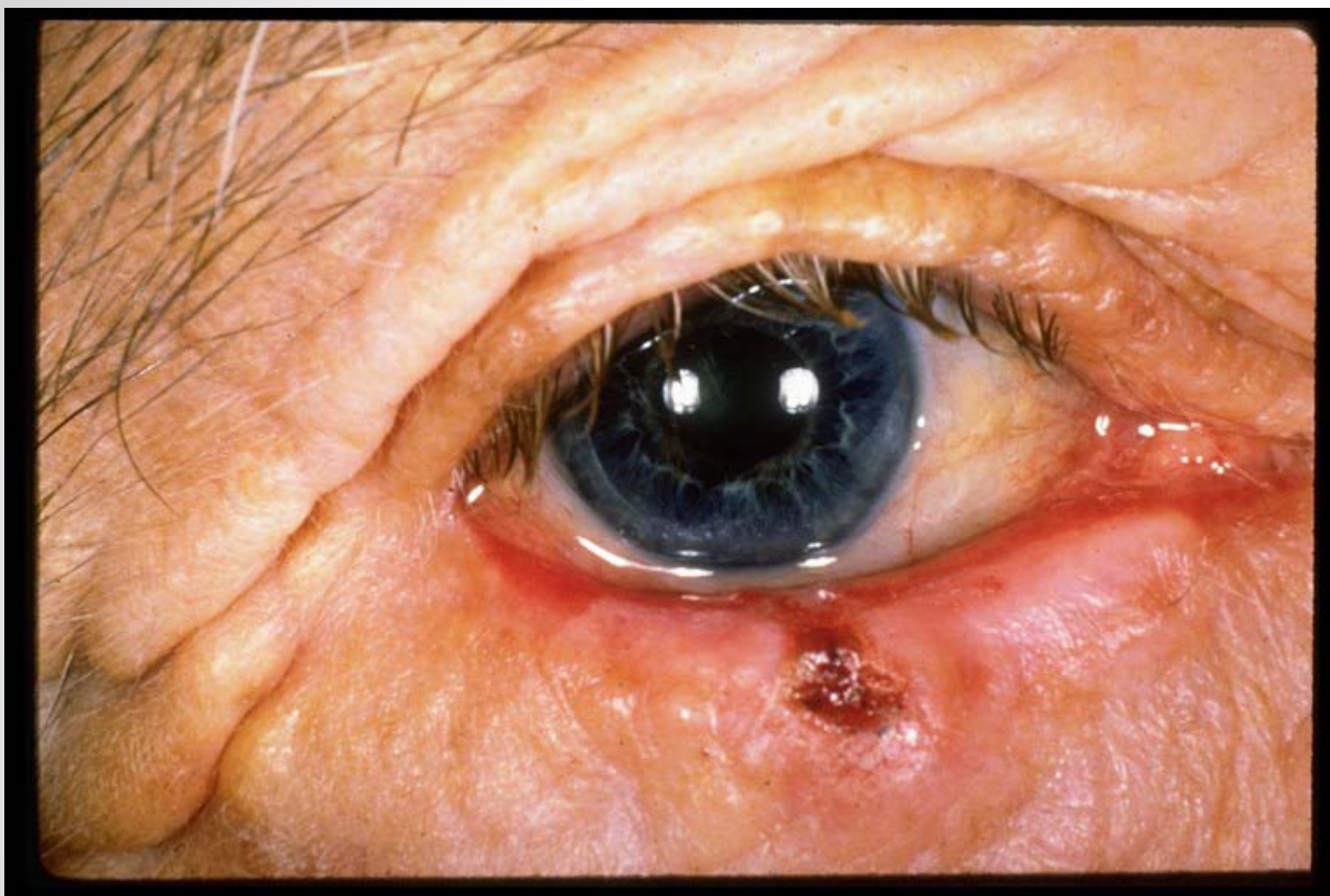


Blepharitis

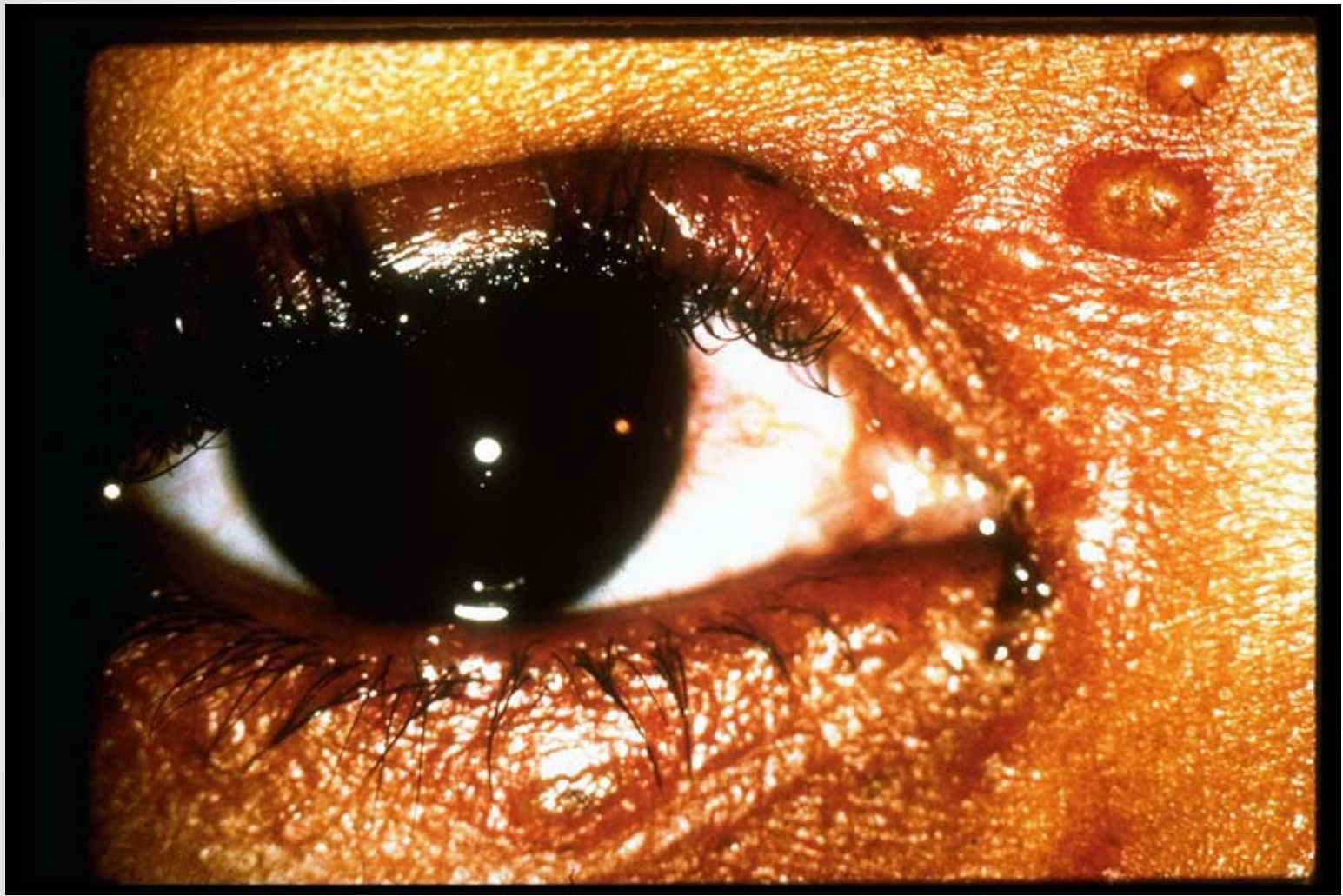



Chalazion

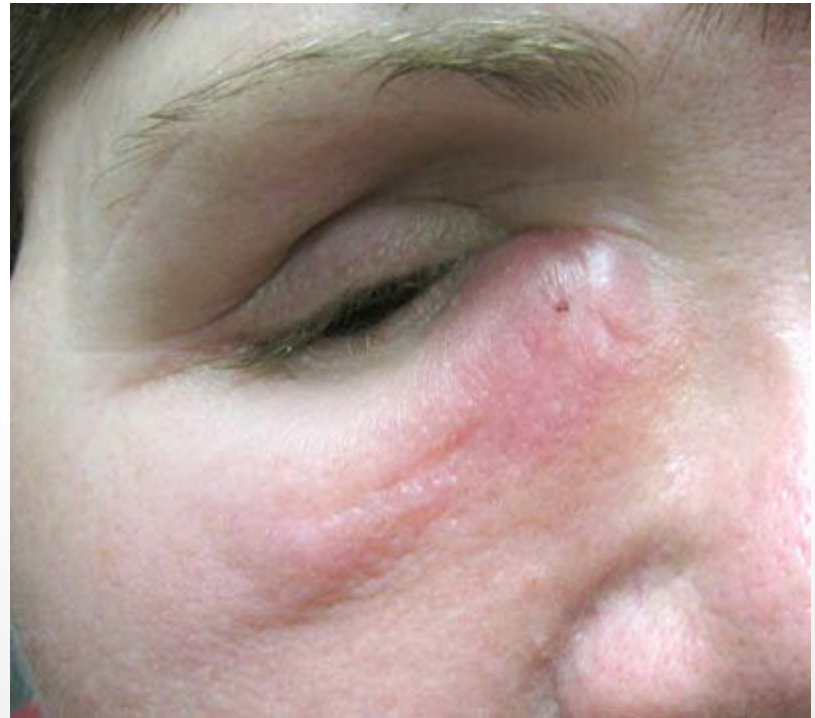
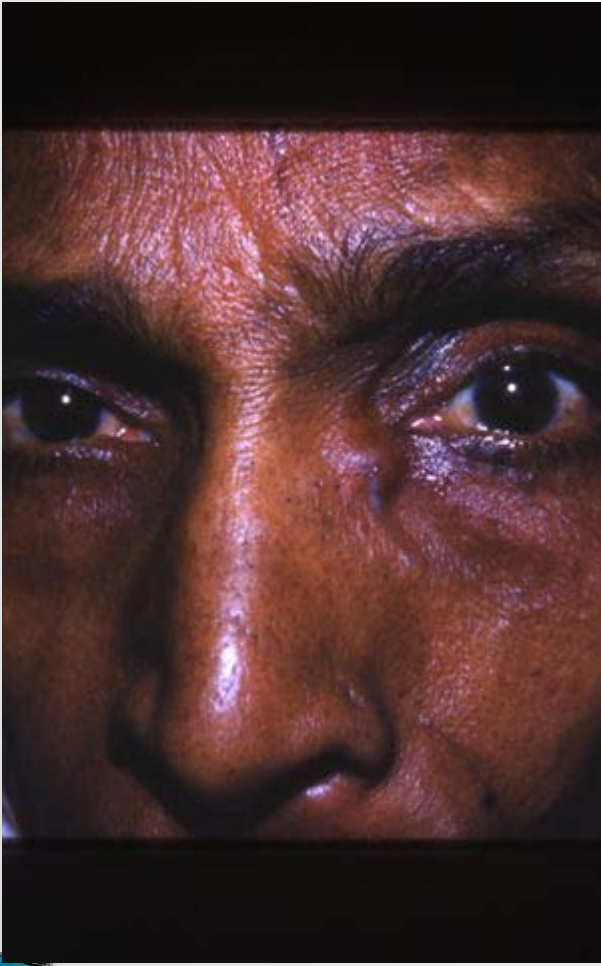
BCC



Mollusca

Dacryocystitis



Ophthalmoscopy

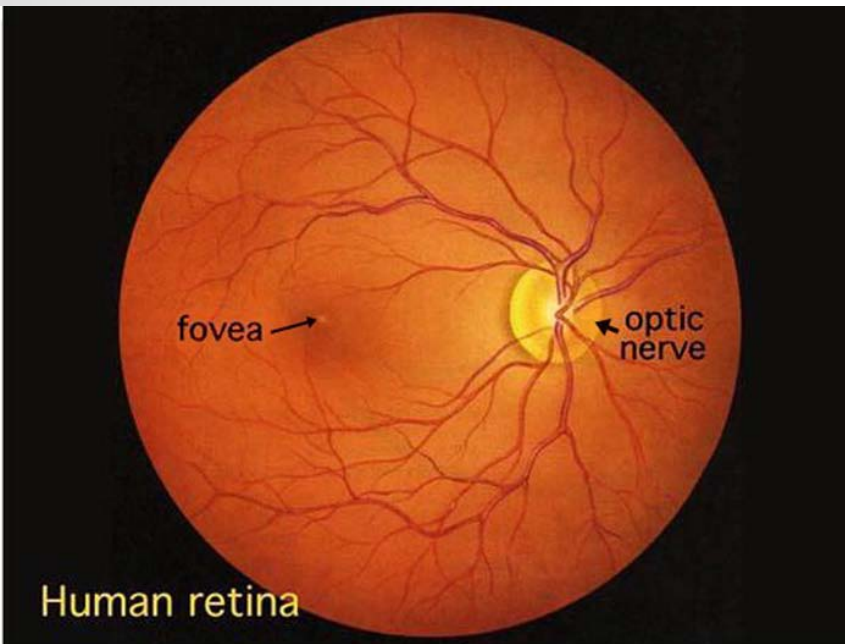
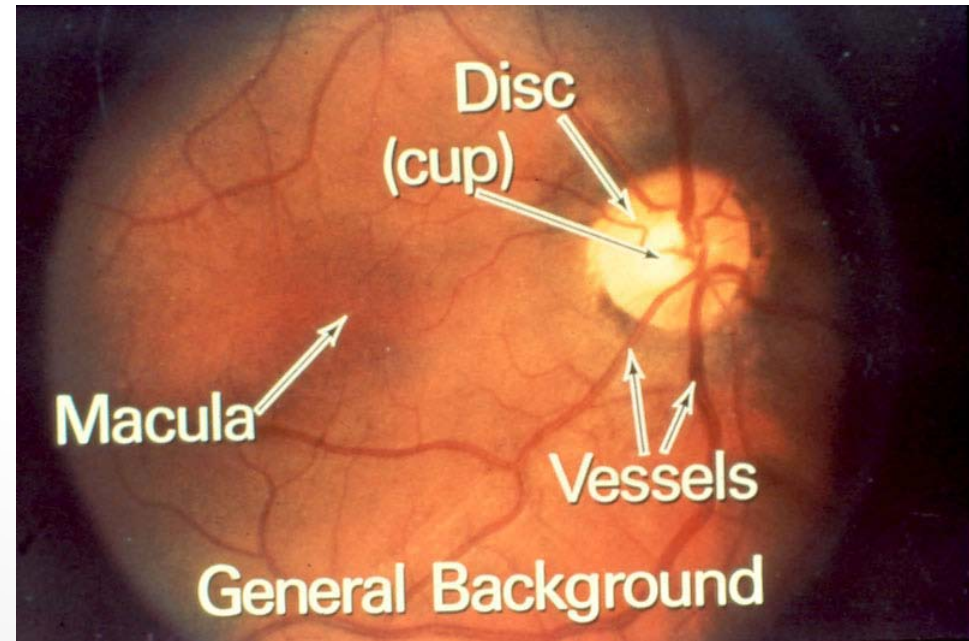
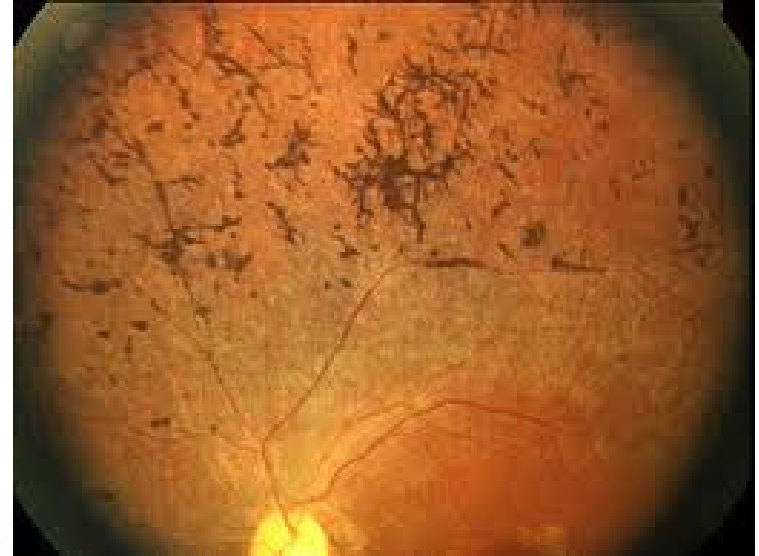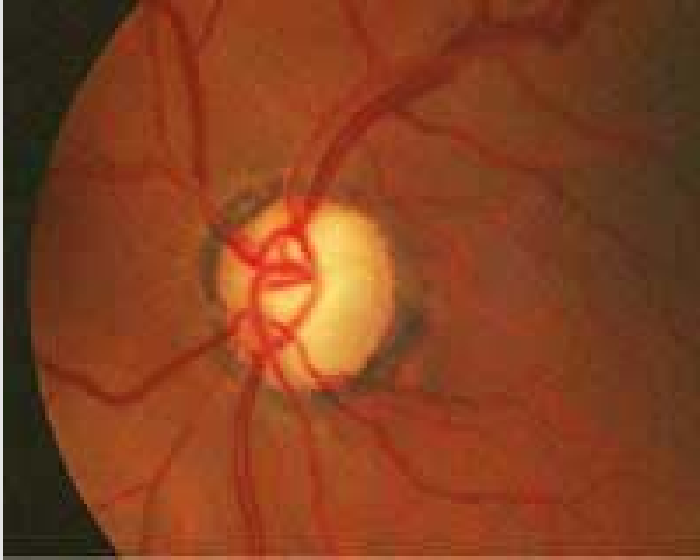


Fig. 1. Human retina as seen through an ophthalmoscope.

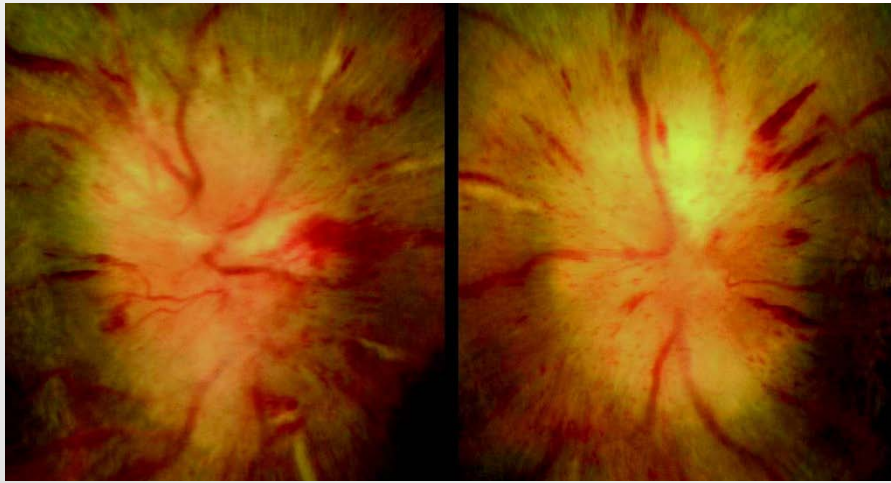
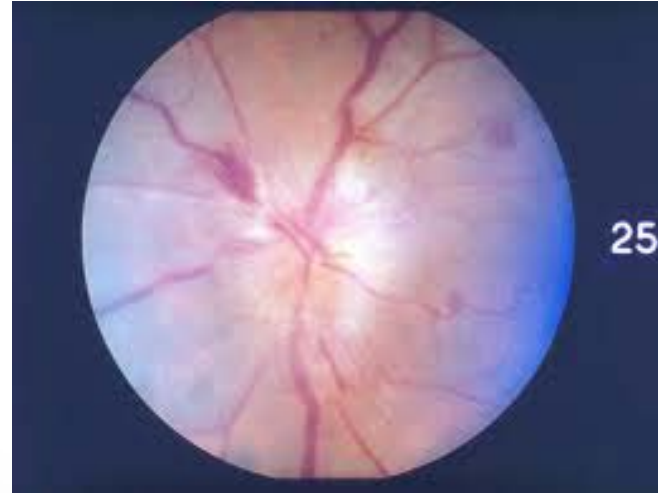
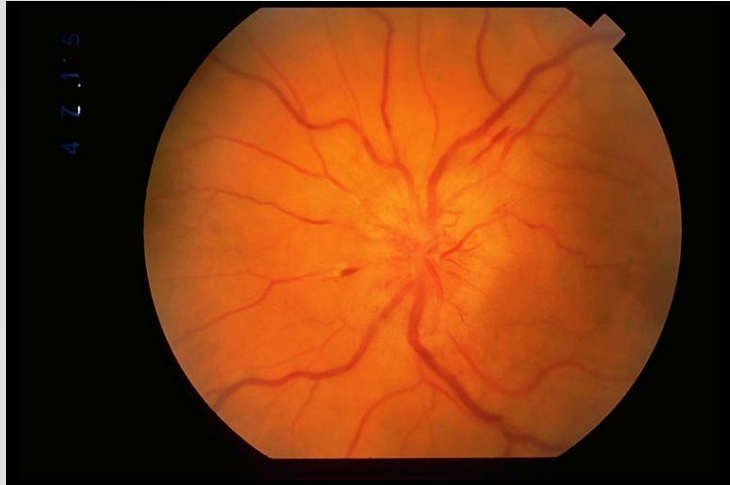
Pigmentation

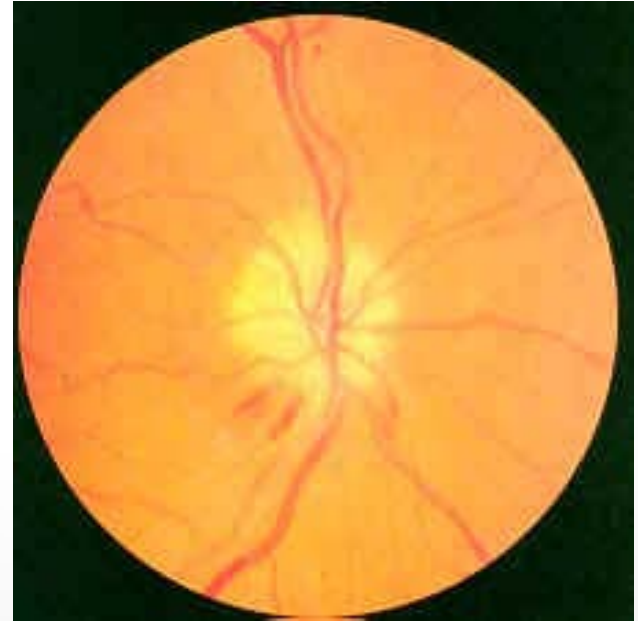
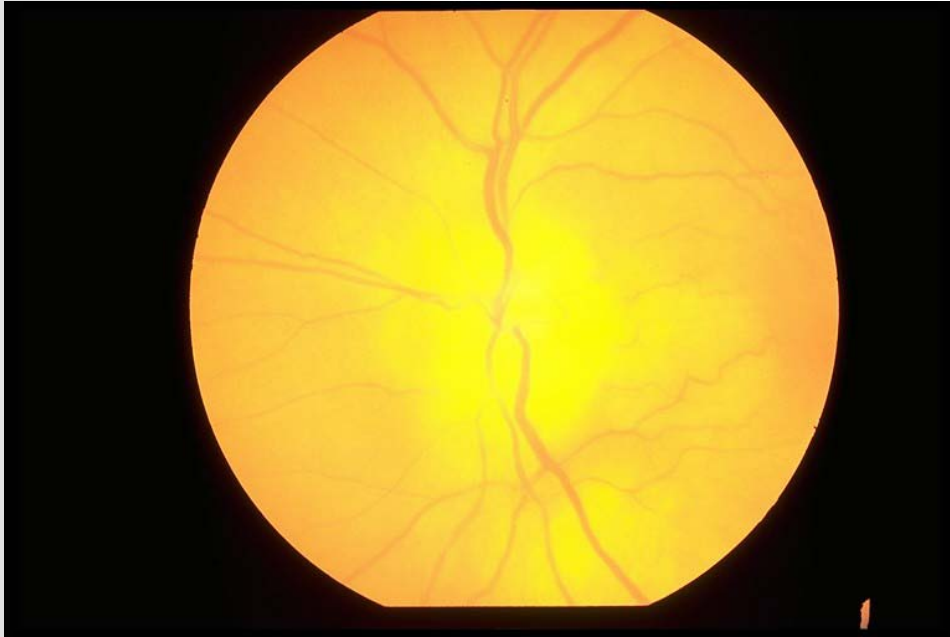


RP

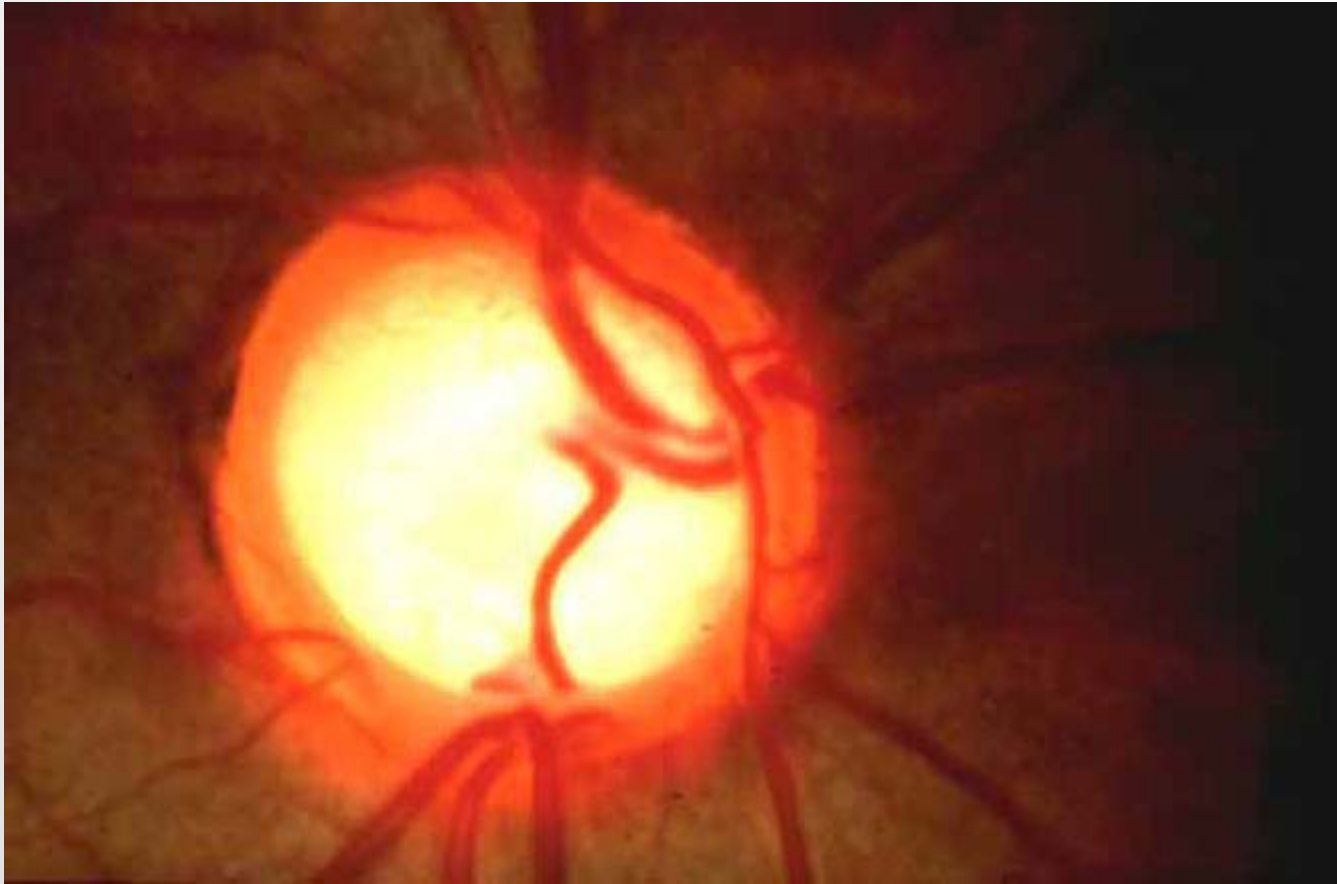
Papilloedema



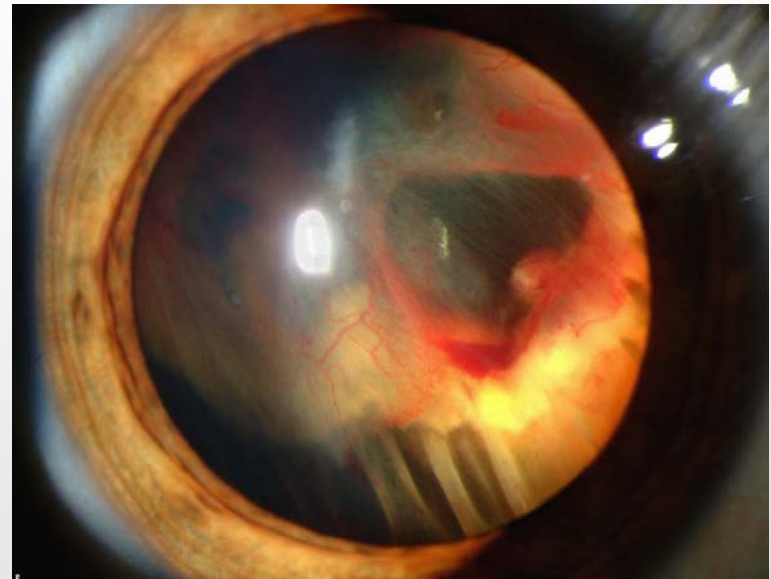
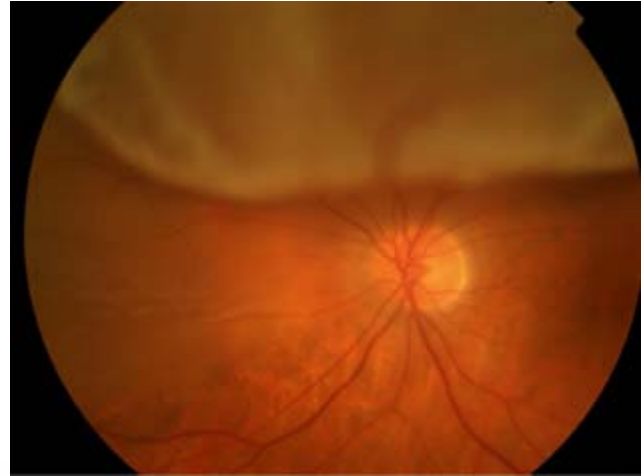
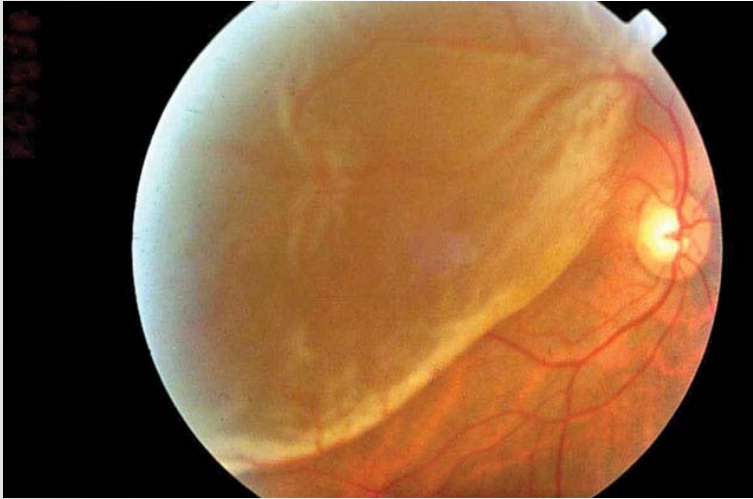
TA



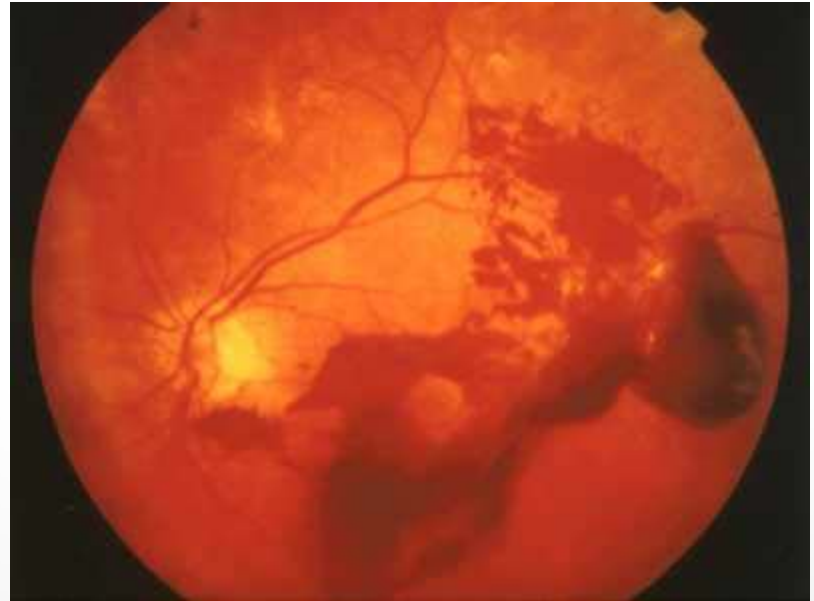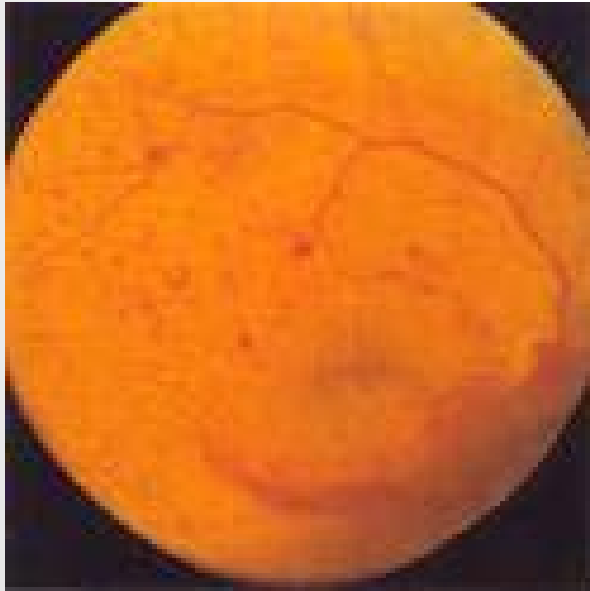Glaucoma Cupping



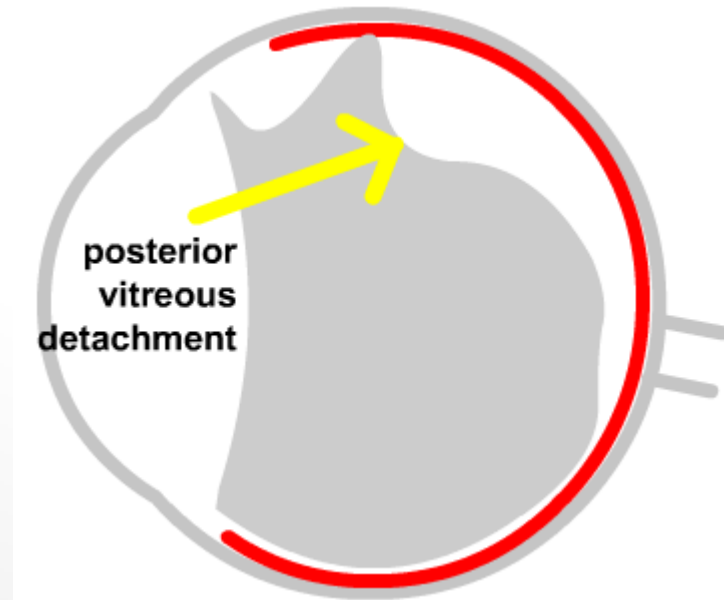
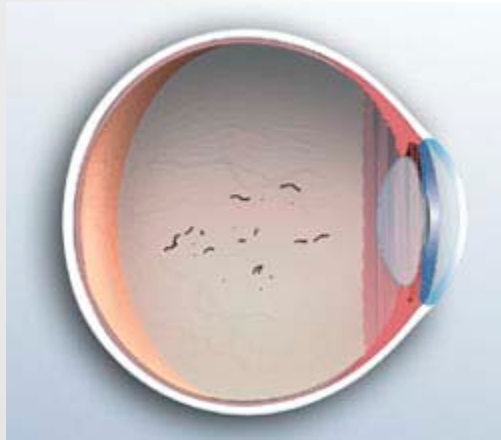
Retinal Detachment



Vitreous Haemorrhage

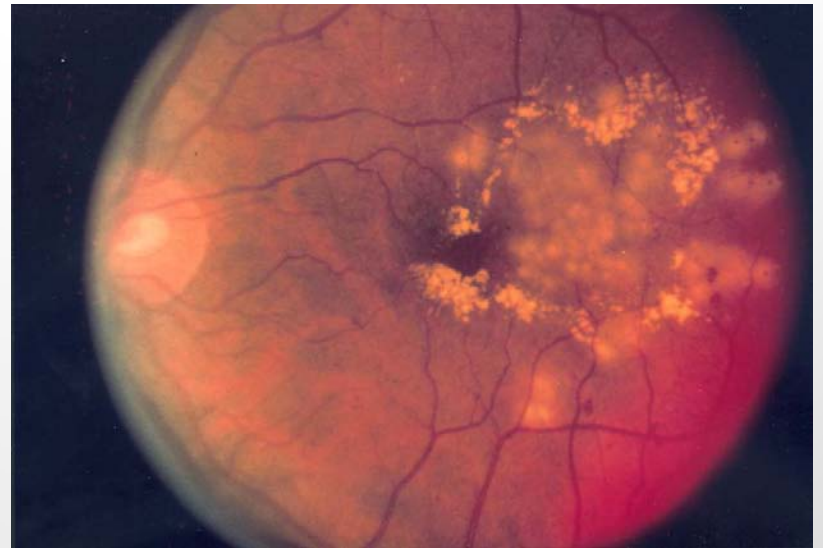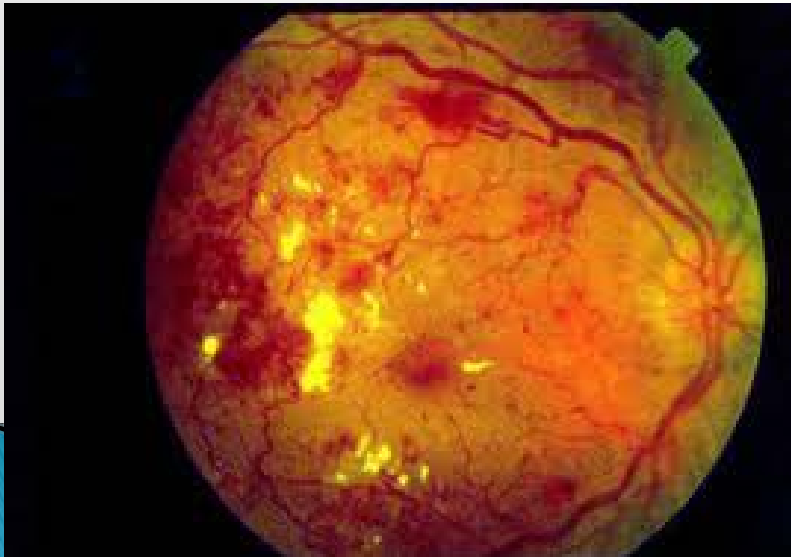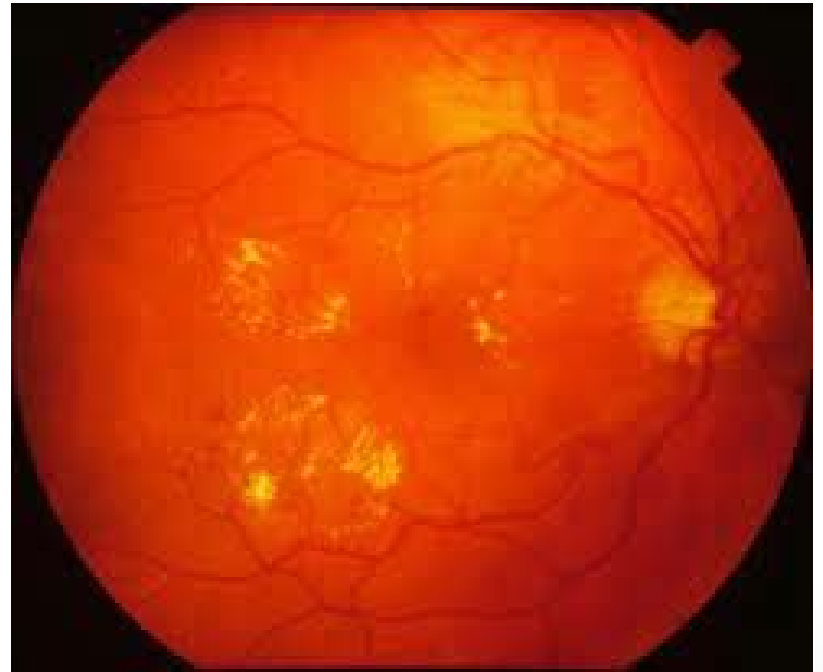


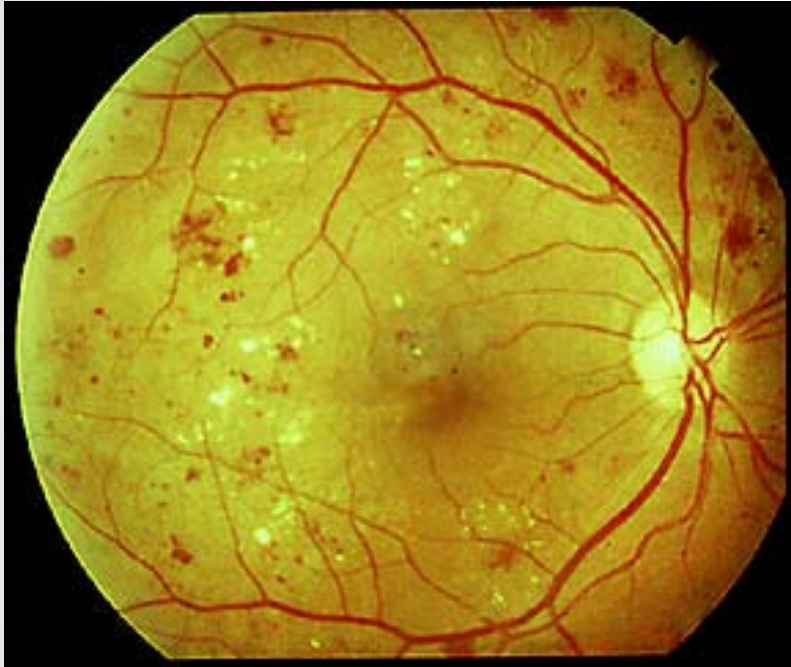Vitreous Detachment



Quiz

Diabetic



Discussion